

Review Article

Side effects of deep brain stimulation in Parkinson's disease: Recommendations

Fardin Nabizadeh*, Maedeh Khodkam

Neuroscience Research Group (NRG), Universal Scientific Education and Research Network (USERN), Tehran, Iran

Abstract. Parkinson's disease (PD) is one of the most common neurodegenerative disorders. Recently, deep brain stimulation (DBS) was proposed as a potential therapeutic approach for PD patients. This procedure has side effects that can be divided into three categories: stimulation-related, surgery-related, and hardware-related side effects. Stimulation-related complications are also divided into motoric such as paresthesia and dysarthria, while non-motor contains cognitive decline and depression. The most important complication related to surgery is intracerebral hemorrhage (ICH). Side effects related to hardware consist mainly of erosion and infections. Choosing the appropriate patient for DBS implantation has a critical role in reducing side effects. Also, adaptive or closed-loop DBS stimulates the brain by adjusting the parameters in response to feedback from the body and produce electrical flow in appropriate time. In addition, new directional leads provide the ability to shape and steer the current to avoid stimulation of unwanted regions. Moreover, using magnetic resonance imaging (MRI) instead of microelectrode recording (MER) allows surgery under general anesthesia and reduces the risk of ICH. Also, interleaving stimulation (ILS) can be a second option for those patients for whom conventional programming does not effective. Choosing the right trajectory and keeping a distance from the vascular areas during lead placement also reduces the risk of hemorrhage.

Keywords: Deep brain stimulation; side effects; adaptive DBS; directional leads; microelectrode recording; Parkinson's disease.

Introduction

Parkinson's disease [1] is the second most common neurodegenerative disorder, and more than one million people in the United States are affected [2]. PD occur often between the age of 55 to 65 and the incidence rate is 1%-2% in people above the age of 60 years [3]. The first-line treatment option for these patients is the use of dopaminergic drugs, which often cause motor disabilities [4]. Another treatment option is the use of Deep Brain Stimulation (DBS), which is an invasive approach, while it has been shown to have considerable therapeutic potential [5]. DBS contains implanting electrodes in targeted areas in the brain and then producing electrical impulses for stimulating the neuron fibers (**Fig. 1**) [3]. However recent studies demonstrated that this procedure also may induce side effects, which may be due to the various factors such as hardware or surgical procedure or even due to stimulation, which leads to various motor and neuropsychiatric problems, and also influence the quality of life in patients under such treatment [6].

Nowadays, by the progress made in this field, and also utilizing new technologies and previous experiences, the side effects of DBS can be preventable. The purpose of this study is to review the side effects and approaches to

minimize them in DBS treatment.

1.1. Stimulation related side effects

In stimulation of targeted nuclei of the brain, the electrical flow may unwantedly spread to other off-targeted regions and cause side effects [7]. The side effects can be clustered into two categories including motor and non-motor side effects.

1.1.1. Motor side effects

Motor complications are not easily recognizable because of the association with the disease progression and the dose reduction of the medications. Speech problems are proposed as an unwanted effect and may occur or aggravate in patients with DBS [8] and also are significantly related to the amplitude period and stimulation duration [9]. Recent studies demonstrated dysarthria is a long-term complication that may be worsened by DBS and increased by the stimulation of the cortico-spinal tract [7, 10]. Study by Tsuboi et al. [11] found that speech and voice problems in Parkinson's patients with DBS were worse than those treated with medication and strained voice and spastic dysarthria occur due to off-target cortico-bulbar tract stimulation [11].

Other findings by the same researchers revealed that

* Corresponding author: Fardin Nabizadeh, MD
 (fardinnabizade1378@gmail.com).

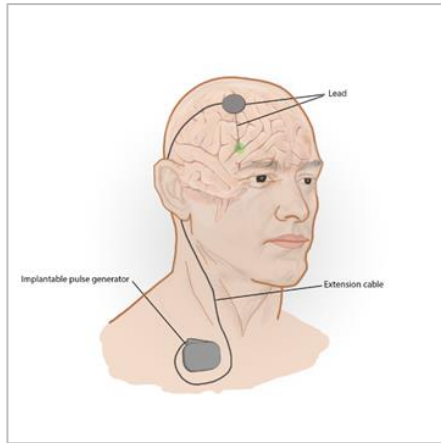


Figure 1. Deep brain stimulation.

incomplete glottal cluster, hyperadduction of the false vocal fold, hyper compression, and asymmetric glottal movement may occur or be aggravated by DBS and consequently lead to strained voice and breathiness in PD patients [12]. Furthermore, dyspnea may also be observed due to the reduced mobility of epiglottis in DBS-treated patients after surgery [13] (Table 1).

Stimulation of the cortico-bulbar tract, which is part of the pyramidal tract, due to current spread causes unwanted contractions while, stimulation of medial lemniscus, causing paresthesia, which are frequent and long-term side effect [14, 15]. According to the findings, eye deviation is also reported as a motor complication of DBS in PD patients that is believed to be the result of the flow spread into the medial oculomotor fiber area [16]. In light of these findings, gait and balance problems may occur which can significantly reduce the quality of life and increase the risk of falls in PD patients [17].

In the Balestrino et al. study, 32 patients with Parkinson's disease under subthalamic nucleuse DBS were followed up for 12 months, and the results revealed 84% of patients gained an average of 6.7 kg of body weight and over half had overweight. This weight gain is probably due to a decrease in dyskinesia which leads to lower energy loss and an increase in electrode distance from the third ventricle which can reduce lateral hypothalamic stimulation, an essential area in the control of metabolism and energy consumption [18].

1.1.2. Non-motor side effects

Many of the side effects caused by the stimulation are reversible and may be eliminated by turning off the stimulation, but the therapeutic effect is diminished [19]. There are multiple reports of neuropsychological problems after DBS implantation in PD patients. Cognitive decline is one of the most common complications and is known to be the result of the disruption of information circuits between the cortico-striatal and the limbic cortex by the spreading of current to that area [20] (Table 1). Neuropsychiatric problems and cognitive decline in reported studies contain difficulty with attention, a decline in psychotic speed in learning and memory [21]. Additionally, disruption of the

limbic cycle also induces alterations in mood function and causes complications such as depression and mania in DBS treated [10, 22]. Depression is a usual side effect after implanting electrodes in the subthalamic nucleus [23] and Globus pallidus internus (GPi), and similar to apathy can progress both due to reduced or discontinued drug use, mainly in cases of rapidly reduced levodopa use [24, 25]. Short-term side effects, such as restlessness and hallucination, may happen. Hallucination may worsen if present prior operation but does not impair quality of life [10].

Older age, less responsiveness to levodopa, and higher volume of white matter lesions are potential risk factors that can induce cognitive decline and should be screened before DBS implantation for preventing such complications [26-28].

Off-targeted stimulation of the areas close to the limbic and substantia nigra reticulate can cause other mood and behavioral disorders including acute uncontrollable laughter, which is rare [29]. Moreover, stimulation of the limbic area may also lead to other rare complications such as impulsivity and aggressive behavior [1, 30]. Based on previous findings, we can demonstrate that many psychological problems after DBS depend on the condition and disorders of the patient before surgery [31].

1.2. Surgery related side effects

The Major complication related to DBS surgery is intracerebral hemorrhage (ICH) [16, 32]. Microelectrode recording (MER), rigid cannulas for lead insertion, hypertension, and bleeding disorder are factors leads to ICH and increase the risk of such side effect [33]. Recent studies revealed the risk of bleeding increases with the MER method and directly correlated with the number of electrodes and occurs between 0.3% and 3.6% per electrode track [34]. ICH can be diagnosed by a CT scan after surgery and rapidly enlarges. Also, one of the causes can be a direct injury to the vessel [35]. A seizure can also occur during or shortly after surgery, and ICH may be one of the factors, while it appears to be rare after discharge [36, 37]. Also, symptomatic brain edema is one of the surgery-related side effects which is noninfectious, non-hemorrhagic, and delayed, and more common in re-implantation lead than new implantation. It may occur along with a seizure a few days after surgery while a CT scan demonstrates no edema [38]. Pulmonary complications are also listed as side effects due to surgical procedures in DBS-treated patients that contain pulmonary embolism and pneumonia (Table 1), however, they are a common side effect after all types of surgery [39].

As well, misplaced lead is considered as one of the challenges during DBS implantation, which may occur as a result of multiple reasons. The inaccuracy of stereotactic frame, MRI or CT scan error, the fault of surgeon or radiologist, and lack of knowledge of anatomy are the factors that cause displacement of lead [40, 41].

1.3. Hardware related side effects

Hardware-related complications can occur in any part

TABLE 1
Side effects of deep brain stimulation in Parkinson's disease

Stimulation related		Surgery related	Hardware
Motor / Target	Non-motor / Target		
Dysarthria / STN/GPi/Vim	Hypomania / STN	Intracerebral hemorrhage	Post-surgery infection in area
Dizziness / STN/Vim	Psychotic symptoms / STN	Post-surgery headache	Disseminated infection
Imbalance / STN	Apathy / STN, GPi	Ventricle puncture	Coughing
Paresthesias / STN, Vim	Aggressive behavior / STN	Partial hematoma	Skin infection
Eye deviation / STN, Vim	Suicide / STN	Pneumocephalus	Erosion
Weight gain / STN	Cognitive impairments / STN, GPi	Edema	Lead fracture
Dyspnea / STN	Behavior problems / STN, GPi	Seizure	Lead migration
Freezing / STN, GPi	Acute uncontrollable laughter / STN	Deep venous thrombosis	Lead failure
Rigidity / STN, GPi	Depression / STN, GPi	Pneumonia	IPG malfunction
Resting tremor / STN, GPi	Sexual disturbance / STN	Deep cerebral venous hemorrhage	Other parts fracture or failure
Bradykinesia / STN, GPi	Hallucination / STN	Sterile seroma	IPG migration
Gait abnormalities / STN, GPi	Restlessness / STN	Pulmonary embolism	Pain in IPG area
Dysphonia / STN	Impulsivity / STN	Misplaced lead	
Postural instability / STN, Vim	Visual phenomena / GPi		
Apraxia of eyelid opening / STN	Anxiety / STN		
Muscular cramp / STN			
Dystonia / STN			
Ataxia / STN, Vim			
Muscle contraction / STN, GPi, Vim			
Heart sensation / GPi			
Sweating / STN			
Strained voice / STN			
Breathiness / STN			
Dyskinesias / STN			
Dysphagia / STN, GPi			
Swallowing problems / STN, GPi			

of the DBS system including the implantable pulse generator (IPG), extension cable, and lead (Figure 1)[42]. As the DBS device is considered a foreign body, skin erosion and infections are occur commonly as a consequence of hardware placement [43, 44]. According to previous investigations, most infections occur at the IPG Pocket location, and the junction between lead and extension is the usual site of erosion. Furthermore, the erosions are often infectious and Staphylococcus aureus account for it most of the time [45]. Other common sites of infection are the parietal and frontal areas of the head, where the extension wire crosses connect to the lead. Surgery time, short period use of prophylactic antibiotic drugs, and diabetes are risk factors for infection development.

There are two ways of implanting an extension wire: in the first type, the extension wire passes through one side of the neck and divides in front of the chest, then each wire going to its IPG device, while in the second type the wires passing through the two sides of the neck And beneath the clavicle are connected to the IPG on the same side. However, based on findings the first type seems to be more likely to develop infection [46].

Lead migration is also a challenge that can occur usually after a long time in consequence of various factors. Although it can be easily diagnosed by Magnetic resonance imaging (MRI) after surgery, and in case of reduced efficacy, it must be repositioned by the surgeon [47].

Any error and dysfunction in the DBS system may account for side effects, including battery drain, lead fracture, malfunction of the IPG and lead, cable disconnection, IPG dislocation, and pain in the insertion site due to severe shocks, shock, or Other causes [19, 48] (**Table 1**). One of the rare complications reported is coughing, which is thought to occur due to the proximity of the extension cable to the vagus nerve, however, this is the only mechanism that can explain such complication in PD patients treated with DBS [49].

2. Recommendations for minimizing side effects

2.1. Target selecting

Target selection is one of the most critical issues in DBS implanting. Currently, the most identified targets for electrode placement in PD patients are the subthalamic

nucleus [23] and globus pallidus internus (GPi), while many studies have compared these targets and did not report a significant advantage. A study by Boel et al. in an investigation of STN and GPi DBS treated patients found that after three years of follow-up, there was no significant difference in cognitive and psychological outcomes [50]. Okun's study also found little difference in motor performance improvement and cognitive and psychological complications [51]. However, another study found that patients treated with STN DBS had a more significant reduction in dopaminergic drug use, and therefore experienced more cognitive and psychological effects compared to patients with GPi DBS [51]. In contrast, a different study preferred STN because of achieving higher scores in most criteria and suggested it as an ideal target for those with drug-related complications [53].

2.2. Patient selection

In addition to target selection, choosing the appropriate candidate for DBS operation is a v issue in developing future side effects, and improving therapeutic efficiency. Many of the complications experienced after implantation may previously be present and worsened by DBS [28]. Routinely, in most clinical centers, patients with at least five years of progressive Parkinsonism, levodopa responsive with at least 30% improvement in Unified PD Rating Scale (UPDRS) by dopaminergic therapy are chosen for DBS surgery [54, 55]. Besides, the use of DBS in the early stages of the disease is currently being discussed and there were some advantages [23, 56, 57]. However, the early use of DBS may cause several obstacles, including the detection of early-stage symptoms of atypical Parkinson's, which may overlap with Parkinson's disease, and alternatively, later on, symptoms appear [58, 59]. Recent studies indicated older people have more potential for experience side effects such as cognitive decline [28], and also the presence of any mental disorders may trigger psychological complications for that it should be considered when selecting a candidate [31]. Based on different reports anemia, BMI > 30, and diabetes are also related to DBS complications and must be screened by a surgeon and neurologist before implanting [60].

2.3. MRI or MER?; local or general anesthesia

The stimulation field is typically small, and the appropriate outcome depends on its targeting accuracy with minimal deviation, which is said to be less than 2mm for efficient stimulation [61]. For a long time, MRI was only utilized for preoperative imaging and had some difficulties. In this method, the physician was installing the stereotactic head frame on the patient the day before surgery and then performing an MRI scan. One disadvantage is that MRI is time-consuming and it was difficult for patients with motor problems to control their movement during scanning and stay motionless, and additionally, it was more difficult for Parkinson's patients while they are in the off-drug phase and experience a lot of tremors. Though, currently, a combination of MRI and CT scan has been proposed for pre-surgery imaging, which has multiple advantages. This approach allows patients to be on drugs, which makes

patients feel comfortable and improves imaging accuracy and also CT scan significantly reduces the time before surgery. This technique provides a deviation of 0.5-0.6 mm, which significantly minimizes side effects and improves therapeutic outcomes [62-65].

The success of the operation depends on the accuracy of the lead implanting in the target nucleus, which is commonly done by preoperative stereotactic planning, the use of intraoperative MER, and macro electrode stimulation to determine the range between side effects and clinical outcomes [66]. In utilizing MER, the patient must be awake and under local anesthesia for testing the accuracy and efficacy of electrode placement, while surgery in the awake state for older patients and those with physical disabilities, causing problems such as stress and fatigue and reducing their desire to participate. Also, the use of MER during surgery can complicate the process and increase the time it takes, so the incidence of infections increases and, on the other hand, requires a lot of experience [67]. Advances in intraoperative imaging allow direct visualization within DBS implanting [68]. Intraoperative imaging can eradicate our need for conventional, frame-based lead implantation. Furthermore, increased experience and advancement in MRI imaging may allow accurate placement in the patient under general anesthesia without the use of MER, with comparable clinical results [69]. Currently, Electrode placement with direct image guidance by intraoperative real-time imaging is under investigation. This method simplifies the DBS insertion process due to the lack of MER use and the increased tendency of patients [67]. Several reports have stated that this method based on direct imaging has acceptable results compared to using MER. In Starr et al. study, lead insertion for PD patients was performed using a frameless system and intraoperative MRI guidance under general anesthesia. While there is no MER using, results showed significant clinical improvement in outcomes of UPDRS part III 9 months after surgery [70]. In another study that investigated DBS electrode placement under anesthesia using Nexframe and intraoperative CT for lead verification, accuracy was comparable with MER [71]. As previously described the use of MER increases the risk of ICH and also is directly associated with the number of tracks [47, 72].

Surgery under general anesthesia is recommended for those who are not eligible for surgery on the awake condition. Various factors such as severe anxiety and cardiovascular or pulmonary problems lead the patient to have surgery under general anesthesia, and also there are some advantages such as reducing stress and pain in the patient [73]. The use of MR imaging is less accurate than 3D mapping using MER, but advances in MR imaging, better protocols, and higher resolution have allowed many clinical centers to adopt this approach [72, 74]. Implantation on awake state and local anesthesia allows the neurological team to arrive at an appropriate clinical response to improve the symptoms and side effects caused by the spread of electrical current to surrounding tissues [75]. Also using MER and getting the right response increases the length of surgery. DBS implantation can now be performed under general anesthesia, but this modification should not reduce DBS

efficacy and make postoperative management difficult [76]. Baumgarten and colleagues proposed a data-driven or artificial intelligence-based method to predict the pyramidal tract side effect after STN and GPi stimulation. The pyramidal tract side effect is one of the most common side effects of DBS and causes muscle contraction due to the stimulation of cortico-bulbar and corticospinal fibers [14, 77]. This method is based on an artificial neural network and predicts the upper limit of the therapeutic window based on the three-dimensional coordinates of the electrode and the electrical current spread by the stimulation. The therapeutic window is defined by the lower limit, which is the least stimulus required to improve disease symptoms, and the upper limit is defined as the threshold for side effect appearance. Safe surgery can be performed with direct imaging instead of MER, and under general anesthesia, while the time of surgery is significantly reduced, the patient feels comfortable, and the risk of ICH and infection is reduced [76].

2.4. Programming

After DBS insertion, initial programming should be performed. The purpose of this primary programming is to adjust the appropriate stimulation parameters to deliver stimulation to areas responsible for symptoms, as well as to prevent the stimulation of structures that cause side effects and also setting parameters according to drug settings [78]. There are several programming standards, including close bipolar, where the cathode and anode are adjacent to the contacts and ability to limit the spread of current to the unwanted areas, increase the side effect threshold, and providing a wider therapeutic window compared to Monopolar stimulation where the cathode is adjacent to the contact and the anode is in the battery or vice versa [79].

Contemporary adjustment of pulse width and Amplitude also can prevent the current from spreading [78]. Recent reports suggested that the use of low-frequency stimulation (60-80Hz) improves axial symptoms, including the freezing of gait, dysarthria, and postural control [80, 81]. In light of this, shorter pulse width also reduces the activation of surrounding fibers, and reducing the pulse width as standard from 60 μ s to 30 μ s at the primary programming minimizes side effects and improves disease symptoms with less power consumption, although the 30 μ s pulse width may not be optimal but is better than standard 60 μ s [82]. The programmer's physician will always set the constant pulse width and frequency and then gradually increase the voltage to determine the therapeutic outcomes and side effects [83].

The level of rigidity of the muscles is a rapid and permanent responder to stimulation effect and also is suitable for side effect thresholding and DBS adjustment [84]. Costa and colleagues designed a novel system to measure wrist rigidity with a new device that can be used to adjust the appropriate and optimal stimulation parameters to minimize side effects (85). Previously wrist rigidity was scored by a semi-quantitative scale [86].

Interleaving stimulation [ILS] is a new technique for programming that provides more control on stimulation optimization as well as reducing disease symptoms and the

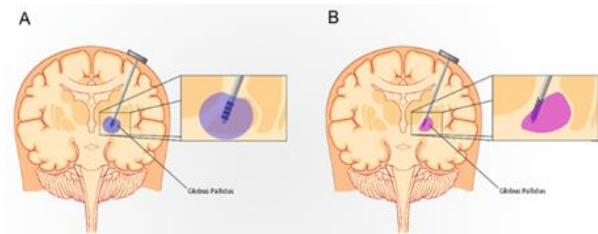


Fig. 2 (A) Conventional leads, (B) Directional leads.

side effects due to stimulation. In the ILS method, there are two programs with their amplitude, pulse width, and active electrode different from each other while switching intermittently [87]. In the Zhang et al. study, ILS was performed on four groups of patients, including stimulation-induced dysarthria and dyskinesia, gait disturbance, and incomplete control of Parkinsonism. The results showed a significant improvement in symptoms as well as a significant decrease in stimulation-induced side effects. They improved an average of 26.9% on UPDRS. Despite this, they suggest ILS as a second option for those who are not able to control PD symptoms by regular programming or exhibit stimulation-induced side effects, since ILS may not be suitable for all [88].

2.5. Directional leads

The dorsolateral segment of STN is the most preferred target for stimulation in PD. Stimulation of this small area by conventional leads with four contacts requires very high accuracy placement, and often it is impossible to prevent the current from spreading to surrounding fibers and thus induce side effects (Fig. 2). Although programming techniques such as ILS or short pulse width are able to increase the threshold of side effects, they cannot handle the problems of omnidirectional stimulation [89, 90].

Conventional DBS technology uses a single-source voltage-controlled stimulation. With the advance of DBS devices, current-controlled systems with multiple independent sources have been developed which allow directional stimulation (Fig. 2) [91]. New directional leads provide the ability to shape and steer the current to avoid stimulation of unwanted regions [92]. One of the most crucial issues in using conventional leads is in the wrong placement of leads, there is no possibility to stimulate targeted areas, and besides in such condition, the only way is increasing stimulation and then current spreading to unwanted regions [89, 93], but directional leads can overcome this limitation and stimulate the targeted areas if displaced [94].

Several types of directional leads are nowadays used, such as the "vercise lead" (Boston scientific), which has eight contacts and allows independent adjustment of the current of each contact [94]. The "HD lead" (Medtronic Eindhoven design center), which has 32 contacts, is more accurate in-depth and capable of steering current [93]. "Direct SUM" (Aleva neurotherapeutics), which has a quadrupolar lead with four rings, increases the side effect threshold [91]. "SureSTIM" [sapiens], which has 32

contacts, allows us to stimulate the optimal area and allow a wider therapeutic window [91].

In the final, a study found that Bipolar directional stimulation increased the side effect threshold compared to the bipolar circular and monopolar directional, and furthermore there is no side effect up to 10 mA amplitude [95].

2.6. Adaptive or closed-loop DBS

In regular DBS called open loop, parameters are set for a while and adjusted by the physician at each visit, and settings and voltage keep constant until the next visit, while the patient's conditions may change [96]. Moreover, there is no guarantee the stimulation remains effective [83]. Nevertheless, in a newly introduced method called adaptive or closed-loop DBS, stimulation is given when needed by adapting real-time stimulation parameters in response to brain feedback which reflects the patient's clinical condition, and in such a technique, the parameters are automatically set and self-adjusted. The purpose of adaptive DBS is to optimize the stimulation according to the patient's condition, as well as reduce side effects, consume less energy and thus longer battery life and provide a greater therapeutic potential [97]. As we can see advances in machine learning technology have good potential to be applied to these devices [91, 98]. The success of this method relies on utilizing accurate biomarkers with high sensitivity and correctly displaying patient conditions for controlling stimulation. One of these biomarkers is oscillations in the beta frequency range (13-30Hz) [99]. The recent finding revealed that adaptive DBS in PD patients significantly reduced speech side effects and improved motor performance compared to conventional DBS in an Acute setting [100]. Moreover, other reports emphasized the better therapeutic outcomes of adaptive DBS compare to regular open-loop devices [97, 101].

2.7. Procedure

One of the ways that should be considered to minimizing hardware and surgical-related side effects is correct implantation of the lead and the other part of the DBS system. The electrode path should be very precise to prevent ICH, and also special attention should be taken to avoid any contact to sulcus, deeper sulci, and ventricles, as well as, there must be at least 2 mm distance from the ventricular wall and rich vascular areas. The surgical plan should be accurately adjusted to avoid any interaction with the dural and cortical vein [102]. Also, a case report study demonstrates choosing a lateral angle in approach may reduce side effects, such as dysarthria and dystonia, while also this lateral angle may protect vascular and reduce the risk of hemorrhage [103]. However, further investigations are necessary to confirm this finding. In addition, to reducing erosions in thin individuals it is better to place the device inside the muscle and away from the skin. Also, nonlinear incision and avoiding placing the device right under the suture line appears to be effective in reducing possible side effects [47]. Furthermore, it should be suggested that to preventing rare complications such as coughing which is related to the vagus nerve, the extension

wire should be far from the vagus in the neck [49].

2.8. Caring

Some medications prescribed may cause complications in a patient with DBS, there is a report revealed that using Mirabegron, which is prescribed for urinary incontinence and triggers dyskinesia in DBS-treated PD patients [104]. Radiation therapy may also disrupt the IPG, for that, this issue needs to be addressed [105].

The role of nursing before and after surgery is vital. The nurse must be acquainted with surgery criteria and should be involved in candidate selection and carry the duties and procedure of the operation step by step. During the hospital, the medical team must be aware of any motor and non-motor symptoms, pain, sleep, constipation, and urinary problems. The nurse should also assist the physician in programming the DBS and report progress and complications rapidly. After being discharged, the nurse should regularly report the results of stimulation and complications such as skin infections and erosions to the therapy team [32, 106, 107].

Conclusion

Many of the side effects of DBS are preventable and can be minimized using new recommendations and techniques. Choosing the right candidate while considering the patient's previous mental disorders and problems, not using intraoperative MER to reduce ICH risk instead of using MR imaging and data-driven method, and also surgery under general anesthesia can be ideal conditions for DBS implantation in PD patients. However, direct imaging during surgery should not reduce accuracy. The use of new technologies such as directional leads dramatically reduces side effects based on findings and is strongly recommended. Also, the application of adaptive DBS provides smart stimulation of the brain nucleus, increasing efficiency, and reducing side effects. Starting the programming with a shorter amplitude can improve the outcomes. If there is no improvement in regular programming, ILS can be an appropriate candidate for reducing complications and reaching therapeutic results. Furthermore, choosing the accurate plan for surgery while considering the distance from rich vascular areas and selecting a more lateral angle can help reduce side effects. Postoperative and post-discharge care is also critical, and patients should be regularly visited, and their progress and side effects monitored. It seems that there is no significant difference between STN and GPi in DBS implantation while side effects were considered, but if drug-related complications exist, the STN may provide better results.

Conflict of Interest

The authors declare no conflicts of interest.

References

1. Temel Y, Kessels A, Tan S, Topdag A, Boon P, Visser-Vandewalle V. Behavioural changes after bilateral subthalamic stimulation in advanced Parkinson disease: a systematic review. *Parkinsonism Relat Disord*. 2006;12(5): 265-272.

2. Heusinkveld LE, Hacker ML, Turchan M, Davis TL, Charles D. Impact of Tremor on Patients With Early Stage Parkinson's Disease. *Front Neurol*. 2018;9:628.
3. Rizek P, Kumar N, Jog MS. An update on the diagnosis and treatment of Parkinson disease. *CMAJ*. 2016;188(16):1157-1165.
4. Marsden CD, Parkes JD. "ON-OFF" effects in patients with parkinson's disease on chronic levodopa therapy. *The Lancet*. 1976;307(7954):292-296.
5. Kogan M, McGuire M, Riley J. Deep Brain Stimulation for Parkinson Disease. *Neurosurg Clin N Am*. 2019;30(2):137-146.
6. Guehl D, Cuny E, Benazzouz A, Rougier A, Tison F, Machado S, et al. Side-effects of subthalamic stimulation in Parkinson's disease: clinical evolution and predictive factors. *Eur J Neurol*. 2006;13(9):963-971.
7. Matias CM, Mehanna R, Cooper SE, Amit A, Lempka SF, Silva D, et al. Correlation among anatomic landmarks, location of subthalamic deep brain stimulation electrodes, stimulation parameters, and side effects during programming monopolar review. *Neurosurgery*. 2015;11 Suppl 2:99-108; discussion -9.
8. Alomar S, King NK, Tam J, Bari AA, Hamani C, Lozano AM. Speech and language adverse effects after thalamotomy and deep brain stimulation in patients with movement disorders: A meta-analysis. *Mov Disord*. 2017;32(1):53-63.
9. Tripoliti E, Zrinzo L, Martinez-Torres I, Frost E, Pinto S, Foltynie T, et al. Effects of subthalamic stimulation on speech of consecutive patients with Parkinson disease. *Neurology*. 2011;76(1):80-86.
10. Fukaya C, Yamamoto T. Deep brain stimulation for Parkinson's disease: recent trends and future direction. *Neurol Med Chir (Tokyo)*. 2015;55(5):422-431.
11. Tsuboi T, Watanabe H, Tanaka Y, Ohdake R, Yoneyama N, Hara K, et al. Distinct phenotypes of speech and voice disorders in Parkinson's disease after subthalamic nucleus deep brain stimulation. *J Neurol Neurosurg Psychiatry*. 2015;86(8):856-864.
12. Tsuboi T, Watanabe H, Tanaka Y, Ohdake R, Yoneyama N, Hara K, et al. Characteristic laryngoscopic findings in Parkinson's disease patients after subthalamic nucleus deep brain stimulation and its correlation with voice disorder. *J Neural Transm (Vienna)*. 2015;122(12):1663-72.
13. Chalif JI, Sitsapesan HA, Pattinson KT, Herigstad M, Aziz TZ, Green AL. Dyspnea as a side effect of subthalamic nucleus deep brain stimulation for Parkinson's disease. *Respir Physiol Neurobiol*. 2014;192:128-133.
14. Tommasi G, Krack P, Fraix V, Le Bas JF, Chabardes S, Benabid AL, et al. Pyramidal tract side effects induced by deep brain stimulation of the subthalamic nucleus. *J Neurol Neurosurg Psychiatry*. 2008;79(7):9-813
15. Mehanna R, Machado AG, Connett JE, Alsaloum F, Cooper SE. Intraoperative Microstimulation Predicts Outcome of Postoperative Macrostimulation in Subthalamic Nucleus Deep Brain Stimulation for Parkinson's Disease. *Neuromodulation: Technology at the Neural Interface*. 2017;20(5):456-463.
16. Kocabicak E, Temel Y. Deep brain stimulation of the subthalamic nucleus in Parkinson's disease: surgical technique, tips, tricks and complications. *Clin Neurol Neurosurg*. 2013;115(11):2318-2323.
17. Hausdorff JM, Gruendlinger L, Scollins L, O'Herron S, Tarsy D. Deep brain stimulation effects on gait variability in Parkinson's disease. *Movement disorders : official journal of the Movement Disorder Society*. 2009;24(11):1688-1692.
18. Balestrino R, Baroncini D, Fichera M, Donofrio CA, Franzin A, Mortini P, et al. Weight gain after subthalamic nucleus deep brain stimulation in Parkinson's disease is influenced by dyskinesias' reduction and electrodes' position. *Neurol Sci*. 2017;38(12):2123-2129.
19. Hariz MI. Complications of deep brain stimulation surgery. *Mov Disord*. 2002;17 Suppl 3:S162-6.
20. Fraraccio M, Pfito A, Sadikot A, Panisset M, Dagher A. Absence of cognitive deficits following deep brain stimulation of the subthalamic nucleus for the treatment of Parkinson's disease. *Arch Clin Neuropsychol*. 2008;23(4):399-408.
21. Combs HL, Folley BS, Berry DT, Segerstrom SC, Han DY, Anderson-Mooney AJ, et al. Cognition and Depression Following Deep Brain Stimulation of the Subthalamic Nucleus and Globus Pallidus Pars Internus in Parkinson's Disease: A Meta-Analysis. *Neuropsychol Rev*. 2015;25(4):439-454.
22. Philipsson J, Sjoberg RL, Yelnik J, Blomstedt P. Acute severe depression induced by stimulation of the right globus pallidus internus. *Neurocase*. 2017;23(1):84-7.
23. Schuepbach WM, Rau J, Knudsen K, Volkmann J, Krack P, Timmermann L, et al. Neurostimulation for Parkinson's disease with early motor complications. *N Engl J Med*. 2013;368(7):610-622.
24. Yin Z, Cao Y, Zheng S, Duan J, Zhou D, Xu R, et al. Persistent adverse effects following different targets and periods after bilateral deep brain stimulation in patients with Parkinson's disease. *J Neurol Sci*. 2018;393:116-127.
25. Antosik-Wojcinska A, Swiecicki L, Dominiak M, Soltan E, Bienkowski P, Mandat T. Impact of STN-DBS on mood, drive, anhedonia and risk of psychiatric side-effects in the population of PD patients. *J Neurol Sci*. 2017;375:342-347.
26. Daniels C, Krack P, Volkmann J, Pinski MO, Krause M, Tronnier V, et al. Risk factors for executive dysfunction after subthalamic nucleus stimulation in Parkinson's disease. *Mov Disord*. 2010;25(11):1583-1589.
27. Blume J, Lange M, Rothenfusser E, Doenitz C, Bogdahn U, Brawanski A, et al. The impact of white matter lesions on the cognitive outcome of subthalamic nucleus deep brain stimulation in Parkinson's disease. *Clin Neurol Neurosurg*. 2017;159:87-92.
28. Bouwijn JP, Derrey S, Lefaucheur R, Fetter D, Rouille A, Le Goff F, et al. Age Limits for Deep Brain Stimulation of Subthalamic Nuclei in Parkinson's Disease. *J Parkinsons Dis* 2016;6(2):393-400.
29. Huang Y, Aronson JP, Pilitsis JG, Gee L, Durphy J, Molho ES, et al. Anatomical Correlates of Uncontrollable Laughter With Unilateral Subthalamic Deep Brain Stimulation in Parkinson's Disease. *Front Neurol*. 2018;9:341.

30. Papuc E, Trojanowski T, Obszanska K, Stelmasiak Z. Aggressive behavior as a rare side effect of subthalamic stimulation in Parkinson's disease. *Neurocase*. 2015;21(2):220-225.
31. Lilleeng B, Dietrichs E. Unmasking psychiatric symptoms after STN deep brain stimulation in Parkinson's disease. *Acta Neurologica Scandinavica*. 2008;117(s188):41-45.
32. Timpka J, Nitu B, Datieva V, Odin P, Antonini A. Device-Aided Treatment Strategies in Advanced Parkinson's Disease. *Int Rev Neurobiol*. 2017;132:453-74.
33. Seijo FJ, Alvarez-Vega MA, Gutierrez JC, Fdez-Glez F, Lozano B. Complications in subthalamic nucleus stimulation surgery for treatment of Parkinson's disease. Review of 272 procedures. *Acta Neurochirurgica*. 2007;149(9):867-76.
34. Binder DK, Rau GM, Starr PA. Risk factors for hemorrhage during microelectrode-guided deep brain stimulator implantation for movement disorders. *Neurosurgery*. 2005;56(4):722-32; discussion -32.
35. Liu JK, Soliman H, Machado A, Deogaonkar M, Rezai AR. Intracranial hemorrhage after removal of deep brain stimulation electrodes. *J Neurosurg*. 2012;116(3):525-528.
36. Seijo F, Alvarez de Eulate Beramendi S, Santamarta Liebana E, Lozano Aragonese B, Saiz Ayala A, Fernandez de Leon R, et al. Surgical adverse events of deep brain stimulation in the subthalamic nucleus of patients with Parkinson's disease. The learning curve and the pitfalls. *Acta Neurochir (Wien)*. 2014;156(8):1505-1512.
37. Janssen ML, Zwartjes DG, Temel Y, van Kranen-Mastenbroek V, Duits A, Bour LJ, et al. Subthalamic neuronal responses to cortical stimulation. *Mov Disord*. 2012;27(3):435-438.
38. Nazzaro JM, Pahwa R, Lyons KE. Symptomatic, non-infectious, non-hemorrhagic edema after subthalamic nucleus deep brain stimulation surgery for Parkinson's disease. *J Neurol Sci*. 2017;6-383:42;
39. Voges J, Hilker R, Botzel K, Kiening KL, Kloss M, Kupsch A, et al. Thirty days complication rate following surgery performed for deep-brain-stimulation. *Mov Disord*. 2007;22(10):1486-1489.
40. Daniluk S, Davies KG, Novak P, Vu T, Nazzaro JM, Ellias SA. Isolation of the brain-related factor of the error between intended and achieved position of deep brain stimulation electrodes implanted into the subthalamic nucleus for the treatment of Parkinson's disease. *Neurosurgery* 2009;64(5 Suppl 2):374-378.
41. Li Z, Zhang JG, Ye Y, Li X. Review on Factors Affecting Targeting Accuracy of Deep Brain Stimulation Electrode Implantation between 2001 and 2015. *Stereotact Funct Neurosurg*. 2016;94(6):351-362.
42. Siddiqui MS, Ellis T, Tatter SS, Foote KD, Okun MS. Deep Brain Stimulation: Patient Selection in Parkinson's Disease, Other Movement Disorders, and Neuropsychiatric Disorders. In: Tarsy D, Vitek JL, Starr PA, Okun MS, editors. *Deep Brain Stimulation in Neurological and Psychiatric Disorders*. Totowa, NJ: Humana Press; 2008. p. 83-98.
43. Beric A, Kelly PJ, Rezai A, Sterio D, Mogilner A, Zonenshayn M, et al. Complications of deep brain stimulation surgery. *Stereotact Funct Neurosurg*. 2001;77(1-4):73-78.
44. Jitkrisadukul O, Bhidayasiri R, Kalia SK, Hodaie M, Lozano AM, Fasano A. Systematic review of hardware-related complications of Deep Brain Stimulation: Do new indications pose an increased risk? *Brain Stimul*. 2017;10(5):967-796.
45. Sillay KA, Larson PS, Starr PA. Deep brain stimulator hardware-related infections: incidence and management in a large series. *Neurosurgery*. 2008;62(2):360-6; discussion 6-7.
46. Kim MS, Jeong JS, Ryu HS, Choi SH, Chung SJ. Infection related to deep brain stimulation in patients with Parkinson disease: Clinical characteristics and risk factors. *J Neurol Sci*. 2017;383:135-141.
47. Falowski SM, Ooi YC, Bakay RA. Long-Term Evaluation of Changes in Operative Technique and Hardware-Related Complications With Deep Brain Stimulation. *Neuromodulation*. 2015;18(8):670-677.
48. Oh MY, Abosch A, Kim SH, Lang AE, Lozano AM. Long-term Hardware-related Complications of Deep Brain Stimulation. *Neurosurgery*. 2002;50(6):1268-1276.
49. Kruger MT, Hirmer TJ, Honey CR. Coughing as a Side Effect of Deep Brain Stimulation due to Peripheral Stimulation of the Vagus Nerve: Case Report. *Stereotact Funct Neurosurg*. 2019;97(3):207-211.
50. Boel JA, Odekerken VJ, Schmand BA, Geurtsen GJ, Cath DC, Figuee M, et al. Cognitive and psychiatric outcome 3 years after globus pallidus pars interna or subthalamic nucleus deep brain stimulation for Parkinson's disease. *Parkinsonism Relat Disord*. 2016;33:90-95.
51. Okun MS, Fernandez HH, Wu SS, Kirsch-Darrow L, Bowers D, Bova F, et al. Cognition and mood in Parkinson's disease in subthalamic nucleus versus globus pallidus interna deep brain stimulation: the COMPARE trial. *Ann Neurol*. 2009;65(5):586-595.
52. Follett KA, Weaver FM, Stern M, Hur K, Harris CL, Luo P, et al. Pallidal versus Subthalamic Deep-Brain Stimulation for Parkinson's Disease. *New England Journal of Medicine*. 2010;362(22):2077-2091.
53. Krause M, Fogel W, Heck A, Hacke W, Bonsanto M, Trenkwalder C, et al. Deep brain stimulation for the treatment of Parkinson's disease: subthalamic nucleus versus globus pallidus internus. *Journal of neurology, neurosurgery, and psychiatry*. 2001;70(4):464-470.
54. Morishita T, Rahman M, Foote KD, Fargen KM, Jacobson CE, Fernandez HH, et al. DBS candidates that fall short on a levodopa challenge test: alternative and important indications. *Neurologist* 2011;17(5):263-268.
55. Welter ML, Houeto JL, Tezenas du Montcel S, Mesnage V, Bonnet AM, Pillon B, et al. Clinical predictive factors of subthalamic stimulation in Parkinson's disease. *Brain*. 2002;125(3):575-583.
56. Okun MS, Foote KD. Parkinson's disease DBS: what, when, who and why? The time has come to tailor DBS targets. Expert review of neurotherapeutics. 2010;10(12):1847-1857.

57. Verhagen Metman L, Pal G, Slavin K. Surgical Treatment of Parkinson's Disease. *Curr Treat Options Neurol*. 2016;18(11):49.
58. Mestre TA, Espay AJ, Marras C, Eckman MH, Pollak P, Lang AE. Subthalamic nucleus-deep brain stimulation for early motor complications in Parkinson's disease-the EARLYSTIM trial: early is not always better. *Mov Disord*. 2014;29(14):1751-1756.
59. Deuschl G, Schupbach M, Knudsen K, Pinski MO, Cornu P, Rau J, et al. Stimulation of the subthalamic nucleus at an earlier disease stage of Parkinson's disease: concept and standards of the EARLYSTIM-study. *Parkinsonism Relat Disord*. 2013;19(1):56-61.
60. Hu K, Moses ZB, Hutter MM, Williams Z. Short-Term Adverse Outcomes After Deep Brain Stimulation Treatment in Patients with Parkinson Disease. *World Neurosurg*. 2017;98:365-374.
61. Richardson RM, Ostrem JL, Starr PA. Surgical repositioning of misplaced subthalamic electrodes in Parkinson's disease: location of effective and ineffective leads. *Stereotact Funct Neurosurg*. 2009;87(5):297-303.
62. Pinski MO, Herzog J, Falk D, Volkmann J, Deuschl G, Mehdorn M. Accuracy and distortion of deep brain stimulation electrodes on postoperative MRI and CT. *Zentralbl Neurochir*. 2008;69(3):144-147.
63. Barnaure I, Pollak P, Momjian S, Horvath J, Lovblad KO, Boëx C, et al. Evaluation of electrode position in deep brain stimulation by image fusion (MRI and CT). *Neuroradiology*. 2015;57(9):903-908.
64. Hamid NA, Mitchell RD, Mocroft P, Westby GW, Milner J, Pall H. Targeting the subthalamic nucleus for deep brain stimulation: technical approach and fusion of pre- and postoperative MR images to define accuracy of lead placement. *J Neurol Neurosurg Psychiatry*. 2005;76(3):409-414.
65. Wang Y, Liu Z-y, Dou W-c, Ma W-b, Wang R-z, Guo Y. Application of Preoperative CT/MRI Image Fusion in Target Positioning for Deep Brain Stimulation. *Chinese Medical Sciences Journal*. 2016;31(3):161-167.
66. Mirzadeh Z, Chapple K, Lambert M, Dhall R, Ponce FA. Validation of CT-MRI fusion for intraoperative assessment of stereotactic accuracy in DBS surgery. *Mov Disord*. 2014;29(14):1788-95.
67. Strauss I, Kalia SK, Lozano AM. Where are we with surgical therapies for Parkinson's disease? *Parkinsonism & Related Disorders*. 2014;20:S187-S191.
68. Slavin KV, Thulborn KR, Wess C, Nersesyan H. Direct Visualization of the Human Subthalamic Nucleus with 3T MR Imaging. *American Journal of Neuroradiology*. 2006;27(1):80-84.
69. Ko AL, Ibrahim A, Magown P, Macallum R, Burchiel KJ. Factors Affecting Stereotactic Accuracy in Image-Guided Deep Brain Stimulator Electrode Placement. *Stereotact Funct Neurosurg*. 2017;95(5):315-324.
70. Tarr PA, Martin AJ, Ostrem JL, Talke P, Levesque N, Larson PS. Subthalamic nucleus deep brain stimulator placement using high-field interventional magnetic resonance imaging and a skull-mounted aiming device: technique and application accuracy. *J Neurosurg*. 2010;112(3):479-490.
71. Burchiel KJ, McCartney S, Lee A, Raslan AM. Accuracy of deep brain stimulation electrode placement using intraoperative computed tomography without microelectrode recording. *J Neurosurg*. 2013;119(2):301-6.
72. Kloc M, Kosutzka Z, Steno J, Valkovic P. Prevalent placement error of deep brain stimulation electrode in movement disorders (technical considerations). *Bratisl Lek Listy*. 2017;118(11):647-53.
73. Blasberg F, Wojtecki L, Elben S, Slotty PJ, Vesper J, Schnitzler A, et al. Comparison of Awake vs. Asleep Surgery for Subthalamic Deep Brain Stimulation in Parkinson's Disease. *Neuromodulation*. 2018;21(6):541-7.
74. Patel N, Plaha P, Gill S. Magnetic resonance imaging-directed method for functional neurosurgery using implantable guide tubes. *Neurosurgery*. 2007;61:358-65; discussion 65.
75. Pollak P, Krack P, Fraix V, Mendes A, Moro E, Chabardes S, et al. Intraoperative micro- and macrostimulation of the subthalamic nucleus in Parkinson's disease. *Mov Disord*. 2002;17 Suppl 3:S155-61.
76. Baumgarten C, Haegelen C, Zhao Y, Sauleau P, Jannin P. Data-Driven Prediction of the Therapeutic Window during Subthalamic Deep Brain Stimulation Surgery. *Stereotact Funct Neurosurg*. 2018;96(3):142-50.
77. Baumgarten C, Zhao Y, Sauleau P, Malrain C, Jannin P, Haegelen C. Improvement of Pyramidal Tract Side Effect Prediction Using a Data-Driven Method in Subthalamic Stimulation. *IEEE Trans Biomed Eng*. 2017;64(9):2134-41.
78. Bari AA, Fasano A, Munhoz RP, Lozano AM. Improving outcomes of subthalamic nucleus deep brain stimulation in Parkinson's disease. *Expert Rev Neurother*. 2015;15(10):1151-60.
79. Soh D, Ten Brinke TR, Lozano AM, Fasano A. Therapeutic Window of Deep Brain Stimulation Using Cathodic Monopolar, Bipolar, Semi-Bipolar, and Anodic Stimulation. *Neuromodulation*. 2019;22(4):451-5.
80. Sidiropoulos C, Walsh R, Meaney C, Poon YY, Fallis M, Moro E. Low-frequency subthalamic nucleus deep brain stimulation for axial symptoms in advanced Parkinson's disease. *J Neurol*. 2013;260(9):2306-11.
81. Vallabhajosula S, Haq IU, Hwynn N, Oyama G, Okun M, Tillman MD, et al. Low-frequency versus high-frequency subthalamic nucleus deep brain stimulation on postural control and gait in Parkinson's disease: a quantitative study. *Brain Stimul*. 2015;8(1):64-75.
82. Steigerwald F, Timmermann L, Kuhn A, Schnitzler A, Reich MM, Kirsch AD, et al. Pulse duration settings in subthalamic stimulation for Parkinson's disease. *Mov Disord*. 2018;33(1):165-9.
83. Almeida L, Deeb W, Spears C, Oprea E, Molina R, Martinez-Ramirez D, et al. Current Practice and the Future of Deep Brain Stimulation Therapy in Parkinson's Disease. *Semin Neurol*. 2017;37(2):205-14.
84. Picillo M, Lozano AM, Kou N, Puppi Munhoz R, Fasano A. Programming Deep Brain Stimulation for Parkinson's Disease: The Toronto Western Hospital Algorithms. *Brain Stimul* 2016;9(3):425-437.
85. Costa P, Rosas MJ, Vaz R, Cunha JP, editors. *Wrist*

- rigidity assessment during Deep Brain Stimulation surgery. 2015 37th Annual International Conference of the IEEE Engineering in Medicine and Biology Society (EMBC); 2015; 25-29.
86. Benabid AL, Chabardes S, Mitrofanis J, Pollak P. Deep brain stimulation of the subthalamic nucleus for the treatment of Parkinson's disease. *The Lancet Neurology*. 2009;8(1):67-81.
87. Ramirez-Zamora A, Kahn M, Campbell J, DeLaCruz P, Pilitsis JG. Interleaved programming of subthalamic deep brain stimulation to avoid adverse effects and preserve motor benefit in Parkinson's disease. *J Neurol*. 2015;262(3):578-584.
88. Zhang S, Zhou P, Jiang S, Wang W, Li P. Interleaving subthalamic nucleus deep brain stimulation to avoid side effects while achieving satisfactory motor benefits in Parkinson disease: A report of 12 cases. *Medicine (Baltimore)*. 2016;95(49):e5575. 89. ann-v2-id1018.pdf.
90. Dembek TA, Reker P, Visser-Vandewalle V, Wirths J, Treuer H, Klehr M, et al. Directional DBS increases side-effect thresholds-A prospective, double-blind trial. *Mov Disord*. 2017;32(10):1380-1388.
91. Lavano A, Torre AD. Directional Deep Brain Stimulation. *Brain Disorders & Therapy*. 2016;05(03).
92. Pollo C, Kaelin-Lang A, Oertel MF, Stieglitz L, Taub E, Fuhr P, et al. Directional deep brain stimulation: an intraoperative double-blind pilot study. *Brain*. 2014;137(Pt 7):2015-26.
93. van Dijk KJ, Verhagen R, Chaturvedi A, McIntyre CC, Bour LJ, Heida C, et al. A novel lead design enables selective deep brain stimulation of neural populations in the subthalamic region. *J Neural Eng*. 2015;12(4):046003.
94. Timmermann L, Jain R, Chen L, Maarouf M, Barbe MT, Allert N, et al. Multiple-source current steering in subthalamic nucleus deep brain stimulation for Parkinson's disease (the VANTAGE study): a non-randomised, prospective, multicentre, open-label study. *The Lancet Neurology*. 2015;14(7):693-701.
95. Steffen JK, Reker P, Mennicken FK, Dembek TA, Dafsari HS, Fink GR, et al. Bipolar Directional Deep Brain Stimulation in Essential and Parkinsonian Tremor. *Neuromodulation*. 2020.
96. Sasaki F, Oyama G, Sekimoto S, Nuermairaiti M, Iwamuro H, Shimo Y, et al. Closed-loop programming using external responses for deep brain stimulation in Parkinson's disease. *Parkinsonism Relat Disord*. 2021;84:47-51.
97. Little S, Brown P. Debugging Adaptive Deep Brain Stimulation for Parkinson's Disease. *Mov Disord*. 2020;35(4):555-561.
98. Habets JGV, Heijmans M, Kuijf ML, Janssen MLF, Temel Y, Kubben PL. An update on adaptive deep brain stimulation in Parkinson's disease. *Mov Disord*. 2018;33(12):1834-1843.
99. Beudel M, Cagnan H, Little S. Adaptive Brain Stimulation for Movement Disorders. *Prog Neurol Surg*. 2018;33:230-242.
100. Little S, Tripoliti E, Beudel M, Pogosyan A, Cagnan H, Herz D, et al. Adaptive deep brain stimulation for Parkinson's disease demonstrates reduced speech side effects compared to conventional stimulation in the acute setting. *J Neurol Neurosurg Psychiatry*. 2016;87(12):1388-1389.
101. Little S, Pogosyan A, Neal S, Zavala B, Zrinzo L, Hariz M, et al. Adaptive deep brain stimulation in advanced Parkinson disease. *Ann Neurol*. 2013;74(3):449-457.
102. Park CK, Jung NY, Kim M, Chang JW. Analysis of Delayed Intracerebral Hemorrhage Associated with Deep Brain Stimulation Surgery. *World Neurosurg*. 2017;104:537-544.
103. Pourfar MH, Mogilner AY. Lead Angle Matters: Side Effects of Deep Brain Stimulation Improved With Adjustment of Lead Angle. *Neuromodulation*. 2016;19(8):877-881.
104. Murchison AG, Fletcher C, Cheeran B. Recurrence of dyskinesia as a side-effect of mirabegron in a patient with Parkinson's disease on DBS (GPi). *Parkinsonism Relat Disord*. 2016;27:107-108.
105. Guy JB, Levy A, Malkoun N, Chargari C, Bigot L, Magne N. Preventing radiotherapy-induced side effects on deep brain stimulators: the need for a multidisciplinary management. *Br J Neurosurg*. 2014;28(1):107-109.
106. De Rosa A, Tessitore A, Bilo L, Peluso S, De Michele G. Infusion treatments and deep brain stimulation in Parkinson's Disease: The role of nursing. *Geriatr Nurs*. 2016;37(6):434-439.
107. Hunka K, Suchowersky O, Wood S, Derwent L, Kiss ZHT. Nursing time to program and assess deep brain stimulators in movement disorder patients. *The Journal of neuroscience nursing: J Am Assoc Neuroscience Nurses* 2005;37 4:204-210.